

A Retrospective Analysis of 110 Zygomatic Implants in a Single-Stage Immediate Loading Protocol

Stephen F. Balshi, MBE¹/Glenn J. Wolfinger, DMD²/Thomas J. Balshi, DDS³

Purpose: This clinical study using a specific technique was carried out to determine the clinical effectiveness of zygomatic implants under an immediate loading protocol. **Materials and Methods:** All patients treated between May 2000 and October 2006 who received zygomatic implants were included in this retrospective analysis. All patients were treated using the same surgical and restorative protocol. The following data were recorded: gender, age, type of implant, number of implants placed, dimensions of implants, and implant and prosthesis survival. **Results:** Fifty-six consecutive patients (29 women, 27 men; mean age of 60.58 years [range, 38.78 to 84.01]) were treated. All were in need of oral reconstruction and had maxillary atrophy that warranted zygomatic implant placement. One hundred ten zygomatic implants were placed in these 56 patients. Four of the 110 zygomatic implants failed, resulting in a cumulative survival rate of 96.37% with follow-up data no less than 9 months and in excess of 5 years. All four failures were turned-surface zygomatic implants. There have been no failures to date with the titanium anodized-surface zygomatic implants. The prosthesis survival rate was 100.0%. **Conclusion:** In this retrospective analysis of 56 patients receiving 110 zygomatic implants, the survival rate of zygomatic implants was in excess of 96% over a period of 9 months to 5 years. This technique resulted in a stable and predictable prosthetic reconstruction. *INT J ORAL MAXILLOFAC IMPLANTS* 2009;24:335-341

Key words: advanced bone atrophy, dental implants, immediate loading, osseointegration, Teeth in a Day, zygoma

Prosthetic rehabilitation with dental implant-supported prostheses, originally described by Brånemark et al¹ and Adell et al,² has been a widely accepted treatment option for edentulous patients. Different techniques have been used to successfully restore the atrophic maxilla by creating more bone volume and improving bone topography. The techniques used have included iliac block grafting procedures,³ maxillary sinus augmentation,⁴ and Le Fort I osteotomies with interpositional bone grafting.⁵ If adequate bone volume allows, tilted implants^{6,7} or implants in the pterygomaxillary region⁸⁻¹⁰ may provide predictable alternatives for the edentulous maxilla.

This report discusses the use of zygomatic bone for anchorage of dental implants. Although reports are limited, the zygomatic implant has been used in patients with moderate to severe resorption of the maxilla and has demonstrated success in supporting fixed prostheses.¹¹⁻¹⁶ In some reports, the zygomatic implant has been used under immediate functional loading and has demonstrated success.¹⁴⁻¹⁶ The purpose of this retrospective study was to determine the clinical effectiveness of the zygomatic implant in oral implant reconstruction under an immediate loading protocol.

MATERIALS AND METHODS

Patients

Patients who had been treated with immediately loaded zygomatic implants between May 2000 and October 2006 at a private practice (PI Dental Center, Institute for Facial Esthetics, Fort Washington, PA) were analyzed with chart reviews and clinical examinations. Inclusion criteria for zygomatic implant placement were based on the patient's current stable medical condition, his or her ability to undergo dental implant surgery with general anesthesia, and the

¹Chief Operating Officer, CM Ceramics, Mahwah, New Jersey; Director of Biomedical Engineering and Research, PI Dental Center, Institute for Facial Esthetics, Fort Washington, Pennsylvania.

²Prosthodontist, PI Dental Center, Institute for Facial Esthetics, Fort Washington, Pennsylvania.

³Founder and Prosthodontist, PI Dental Center, Institute for Facial Esthetics, Fort Washington, Pennsylvania.

Corresponding author: Dr Stephen F. Balshi, PI Dental Center, 467 Pennsylvania Ave, Suite 201, Fort Washington, PA 19034. Fax: +215-643-1149, Email: balshi2@aol.com

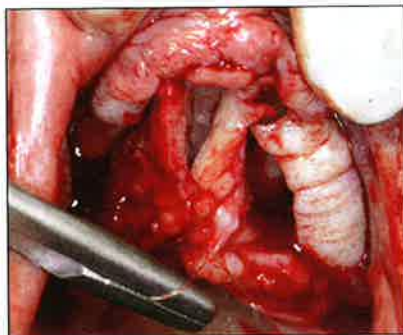


Fig 1 Suturing the palatal soft tissues allows for simpler access to the maxillary crest.

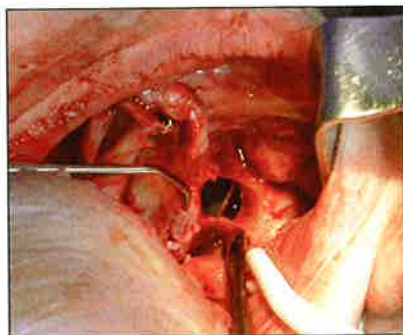


Fig 2 A window is created to aid visual inspection of osteotomy preparation and implant placement.

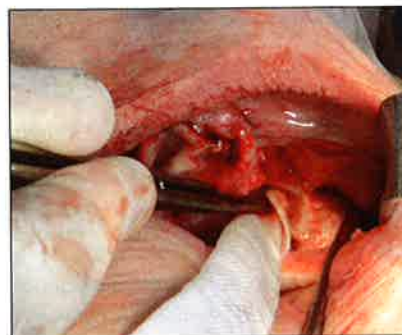

Fig 3 The sinus is packed with sterile gauze.

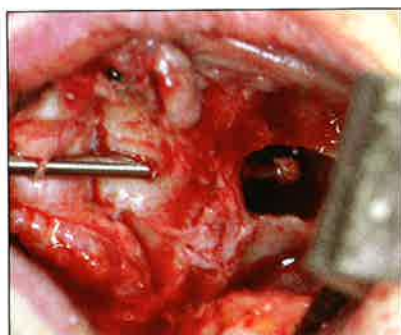


Fig 4 A round bur is used for the first step of the osteotomy preparation.

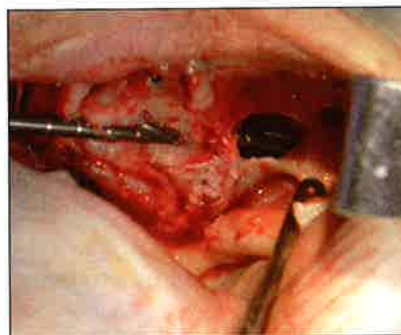


Fig 5 A graduated series of twist drills is used to prepare the osteotomy site to the appropriate diameter.

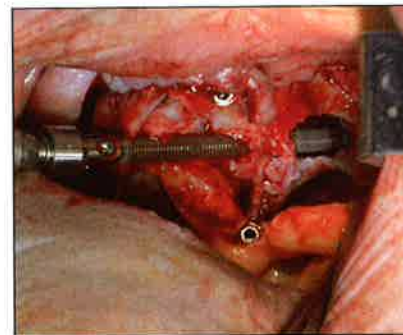


Fig 6 Placement of the zygomatic implant.

presence of sufficient maxillary atrophy to require zygomatic implants. Exclusion criteria were applicable to patients with metabolic bone disease or an unstable systemic condition such as uncontrolled diabetes, untreated hypothyroidism, or a malignancy under current treatment. Patients who were smokers were not excluded from treatment; however, they were strongly encouraged to quit. Radiographic analysis was performed using panoramic, lateral, and anteroposterior cephalometric films.

Surgical Procedure

A blood draw of 60 mL for the production of platelet-rich plasma (PRP) was accomplished immediately prior to the introduction of general anesthesia employing nasal intubation. The PRP production followed the protocol described by Marx.¹⁷ Intraorally, local anesthesia was accomplished using lidocaine hydrochloride (Lignospan Forte, Septodont, New Castle, Delaware) with 1:50,000 epinephrine for regional hemostasis.

Crestal, vertical releasing, and palatal releasing incisions were made to allow for full-thickness flap elevation. The palatal flaps were temporarily sutured together for palatal tissue retraction (Fig 1). With full

retraction, the lateral wall of the sinus was clearly visible to create a slot box or oval window with sufficient opening to remove the sinus membrane at the superior aspect of the antrum (Fig 2). If sinus pathology was detected (eg, polyps), it was treated at this time and the biopsies were sent to Temple Oral Pathology Laboratory (Philadelphia, PA) for analysis. Following debridement, the sinus was packed with epinephrine-soaked ribbon gauze (NuGauze Sterile Packing Strips, Johnson & Johnson, Skillman, NJ) (Fig 3).

Osteotomy preparation was then initiated. Beginning with a round bur, the maxillary bone was penetrated into the floor of the sinus, with the bur carefully guided to begin the entry through the roof of the sinus into the zygoma bone (Fig 4). Then, using a standard series of zygoma drills of graduating diameters (Brånemark System Zygoma Surgical Kit, Nobel Biocare, Yorba Linda, CA), the clinician completed implant site preparation with lateral penetration of the zygoma (Fig 5).

PRP was then placed in a titanium bowl. The Brånemark System zygomatic implant (Nobel Biocare) was rotated through the PRP to coat the implant surface (turned surface or TiUnite surface, Nobel Biocare) and the implant was placed (Fig 6).

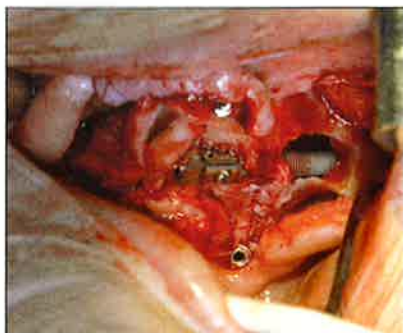


Fig 7 The implant mount screw must be oriented toward the most ideal prosthetic position.

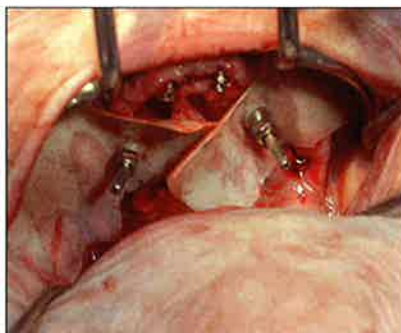


Fig 8 Rubber dam is placed to protect the tissues in the position of the zygomatic implants for connection to the provisional prosthesis.

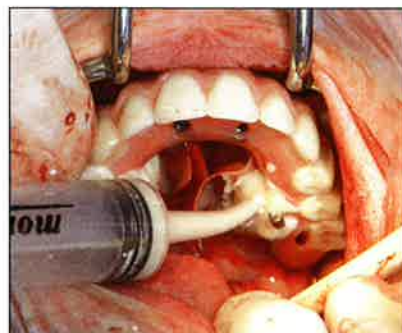


Fig 9 Autopolymerizing acrylic resin was used to connect the zygomatic implant to the provisional prosthesis that was fabricated prior to surgery ad modum Nobel-Guide, thereby connecting the zygomatic implants to the other standard Brånemark System implants.

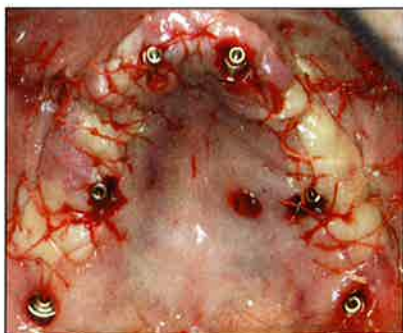


Fig 10 Palatal view of closed maxillary surgical field.

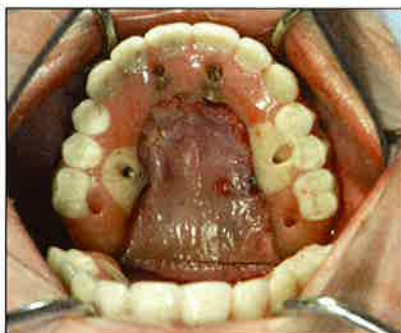

Fig 11 Mirrored occlusal view of acrylic resin provisional prosthesis illustrating the screw-access positions of both the zygomatic and the standard implants.

The rationale behind this technique was to deliver a concentration of growth factors that would assist in wound healing and promote bone remodeling/formation in the osteotomy site. When fully inserted, the last turn of the implant must orient the retaining screw of the implant mount toward the occlusal aspect of the teeth (Fig 7).

Prosthetic Procedure

The zygomatic implant mount was removed and an appropriate abutment was selected to accommodate the prosthetic reconstruction, which would be placed immediately, following the Teeth in a Day protocol.^{15,16,18,19} A prosthetic provisional cylinder with a short guide pin was placed on the zygomatic abutment. The provisional prosthesis was then positioned and the mandible closed to determine the alignment and occlusal relationship.

Following the placement of all abutments and provisional prosthetic cylinders on other standard implants, the rubber dam was marked, punched, and carefully positioned to protect the abutment collar, the implant, and the underlying tissues (Fig 8). A thick mix of autopolymerizing acrylic resin (Jet Tooth Acrylic, Lang Dental, Wheeling, IL) was loaded into a

50-mL monoject disposable syringe. It was then expressed circumferentially around each provisional prosthetic cylinder. A thin coating was also applied to the provisional prosthesis in any area where a connection was intended (Fig 9). If any previously placed prosthetic cylinders were anchored in the prosthesis, the prosthetic screws tightened the prosthesis into the correct position. Additional soft acrylic resin was added to fill visible voids around the provisional prosthetic cylinders.

When the acrylic resin had polymerized completely, all guide pins and prosthetic screws were removed and the prosthesis and rubber dam were disengaged and removed from the patient. Additional acrylic resin was added when needed, and final contours and polishing were accomplished by the laboratory technicians. While the technicians finished the prosthesis, the surgeon thoroughly irrigated the surgical field, including the opening to the sinuses. A narrow suction tip was inserted into each sinus to clear the antral cavity of bone chips and fluids. PRP was applied to the periosteal side of the surgical flaps prior to primary closure. Interrupted Vicryl sutures (4-0 Vicryl sutures FS-2, Johnson & Johnson) were used to tightly close the flaps over the sinus window. In areas

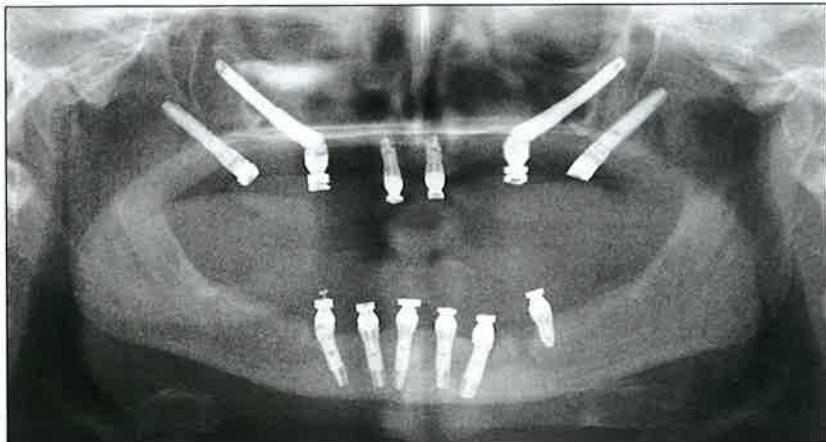


Fig 12a Postoperative panoramic radiograph obtained following delivery of the provisional acrylic resin prosthesis the day of implant placement.

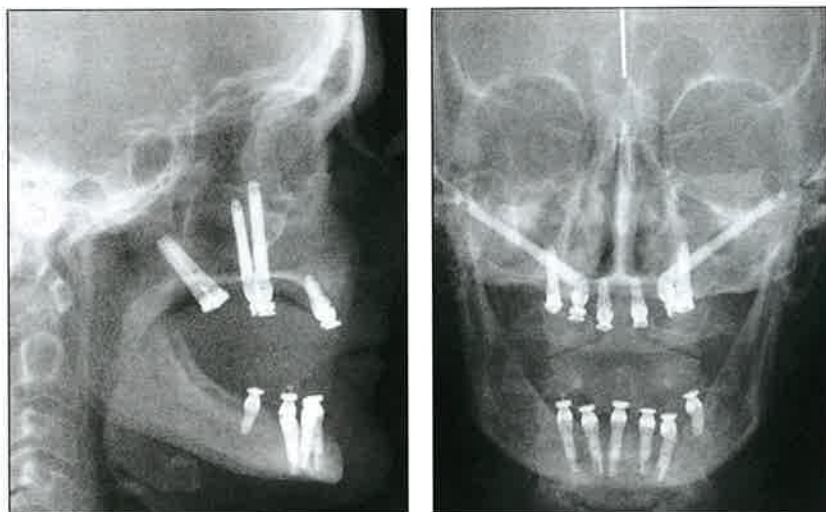


Fig 12b (left) Postoperative lateral cephalometric radiograph obtained following delivery of the provisional acrylic resin prosthesis the day of implant placement.

Fig 12c (right) Postoperative anteroposterior cephalometric radiograph obtained following delivery of the provisional acrylic resin prosthesis the day of implant placement.

where the flap contacted the abutments, a small semi-lunar incision was sometimes required to remove tissue to allow primary approximation of the flaps. Once an airtight closure was achieved (Fig 10), the prosthesis was then placed and all prosthetic screws were uniformly tightened to 10 Ncm (Fig 11). The occlusion was adjusted and verified. An alginate impression was made of the maxillary provisional prosthesis to allow fabrication of an occlusal guard.

The screw access holes were then sealed beginning with a firmly packed cotton pellet and followed by a light-cured provisional resin (Fermit LC, Ivoclar Vivadent, Amherst, NY). Local administration of 1 mL dexamethasone sodium phosphate (4 mg/mL) was accomplished via injections into the palatal and buccal flaps.²⁰

The patient was then extubated and allowed to recover from the general anesthetic. Once the patient was fully conscious, the occlusal guard was delivered, and postoperative panoramic, lateral, and anteroposterior cephalometric radiographs were

made (Fig 12). All patients were prescribed dexamethasone (0.75 mg, 20 tablets: one tablet 4 times/day for 2 days, followed by one tablet 3 times/day for 2 days, one tablet 2 times/day for 2 days, and one tablet 1 time/day for 2 days), ibuprofen (600 mg, 40 tablets: one tablet every 4 to 6 hours), Vicoprofen (hydrocodone bitartrate 7.5 mg and ibuprofen 200 mg, 30 tablets: one tablet every 4 to 6 hours, Amneal Pharmaceuticals, Patterson, New Jersey), penicillin (500 mg, 40 tablets: one tablet 4 times/day), and chlorhexidine (16-oz bottle: rinse with 0.5 oz 2 times/day). Patients were given both ibuprofen and Vicoprofen for pain. They were asked to take ibuprofen for pain and, if the pain was too intense, they were told to switch to Vicoprofen.

The patients presented 7 to 10 days postoperatively for suture removal. The provisional prosthesis remained securely fastened to the abutments. It remained connected for 3 months to provide an undisturbed period of healing with the immediate loading protocol.¹⁹

Table 1 Life Table Analysis

Time	No. of Implants	No. failed	Survival rate	Cumulative survival rate
0-3 mo	110	3	97.27%	97.27%
3-6 mo	107	1	99.07%	96.37%
6-9 mo	106	0	100.0%	96.37%
9-12 m	106	0	100.0%	96.37%
1 y	106	0	100.0%	96.37%
2 y	82	0	100.0%	96.37%
3 y	44	0	100.0%	96.37%
4 y	32	0	100.0%	96.37%
5 y +	11	0	100.0%	96.37%

Following 12 weeks or more of healing, the patient returned to initiate the fabrication of the definitive prosthesis. Occlusal registrations were made prior to the removal of the provisional prosthesis. All abutments were assessed for stability. The final impression was then made using the provisional prosthesis as a matrix. The master cast, with the provisional prosthesis in place, was articulated.¹⁸ The provisional prosthesis was replaced. The definitive prostheses were fabricated as either porcelain-fused-to-gold restorations or milled titanium frameworks supporting individual ceramic crowns (CM Bridge, CM Ceramics, Mahwah, NJ). A second occlusal guard was fabricated to fit the definitive prosthesis. The same series of radiographs was made following the delivery of the definitive prosthesis.

RESULTS

Fifty-six healthy patients (29 women, 27 men) with a mean age of 60.58 years (range, 38.78 to 84.01 years) in need of oral reconstruction in the severely atrophic maxilla were consecutively treated with 110 zygomatic implants and 391 standard Brånemark System implants. Two to six standard implants were placed in the anterior maxilla. All patients were also treated with standard Brånemark System implants in the pterygomaxillary region, thereby providing anchorage both anterior and posterior to the zygoma implants. Fourteen patients received unilateral zygomatic implant treatment; the remaining 42 patients received bilateral zygomatic implant treatment (ranging from two to five zygomatic implants).

Four of the 110 immediately loaded zygomatic implants failed to achieve osseointegration, resulting in a cumulative survival rate of 96.37%. A detailed survival analysis is shown in Table 1. The cumulative survival rate of the standard implants was 97.2% (380 of 391).

Table 2 Distribution of Zygomatic Implants

Implant length	Turned implants	TiUnite implants	Total
30 mm	2	2	4
35 mm	13 (2)	8	21
40 mm	21	6	27
42.5 mm	15 (1)	3	18
45 mm	14 (1)	2	16
47.5 mm	3	4	7
50 mm	8	7	15
52.5 mm	0	2	2
Total	34	34	110

Numbers in parentheses indicate failed implants.

Fifty-seven zygomatic implants were placed into 29 female patients, and 53 were placed into 27 male patients. Three of the four zygomatic implant failures occurred in female patients. Seventy-six of the zygomatic implants were turned-surface implants. When the titanium anodized surface became available on the zygomatic implants, the use of the turned-surface implants stopped. Thus, the more recently treated patients received a total of 34 titanium anodized-surface implants. The distribution of zygomatic implant lengths according to surface is provided in Table 2. All four zygomatic implant failures occurred with turned-surface implants.

All four zygomatic implant failures occurred in the first 4 months following placement. When these patients presented for evaluation, the provisional acrylic resin prosthesis was unscrewed and the zygomatic implant and corresponding provisional cylinder in the prosthesis were removed. Autopolymerizing acrylic resin was used to fill in the void created by the removal of the provisional cylinder. The prosthesis was polished and then returned to the patient. No additional implants were placed, and both the provisional and definitive prostheses were maintained on the remaining implants, thereby yielding a 100% prosthesis survival rate.

Forty-six patients received porcelain-fused-to-gold definitive restorations (Figs 13a and 13b). The remaining 10 patients elected the CM Bridge design as their definitive restoration (Figs 13c and 13d).

DISCUSSION

The severely atrophic maxilla presents a clinical challenge for the treatment team and an emotional and physical challenge for the patient. Patients can be offered extensive grafting procedures, which may include iliac crest transplants,³ sinus elevation surgery with autogenous bone⁴ or a bone substitute,

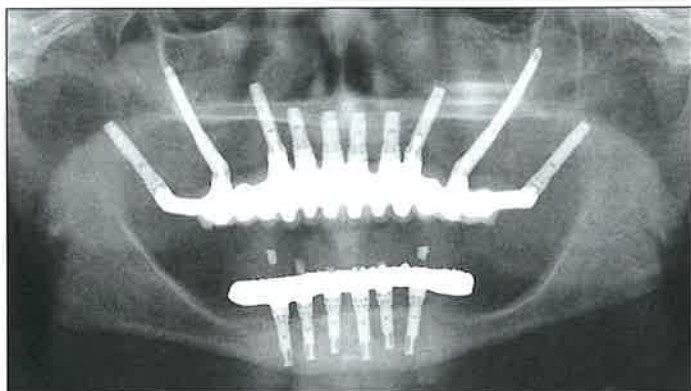


Fig 13a Panoramic radiograph obtained following delivery of definitive porcelain-fused-to-gold prosthesis.

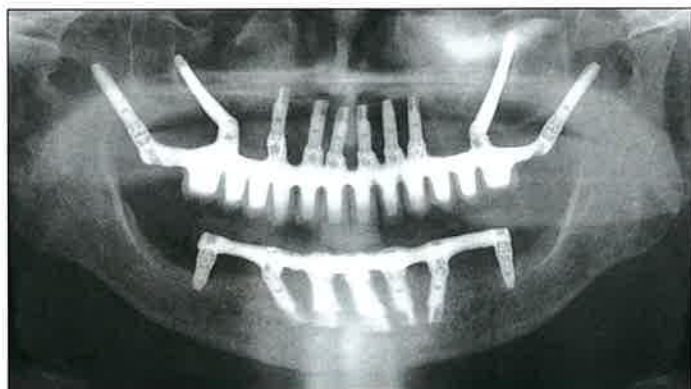


Fig 13c Panoramic radiograph obtained following delivery of definitive CM Bridge prosthesis (milled titanium).

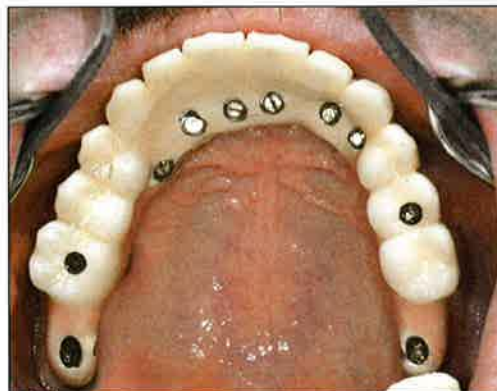


Fig 13b Occlusal view of definitive porcelain-fused-to-gold prosthesis.

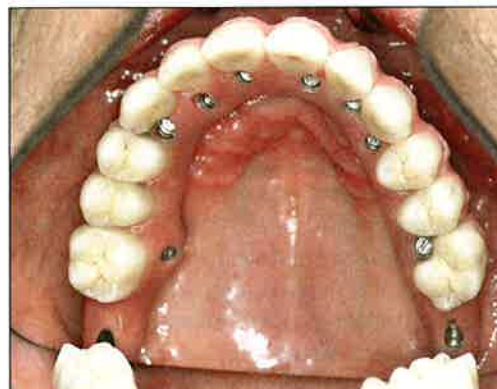

Fig 13d Occlusal view of definitive CM Bridge prosthesis.

onlay segmental grafting or Le Fort procedures⁵ with interpositional grafting. All grafting procedures are invasive, generally requiring a donor site with associated morbidity and potential surgical sequelae. Additionally, all grafts require maturation prior to implant placement. It is well known that implants in grafted bone do not enjoy as high a success rate as implants placed in native bone.²¹ Patients undergoing major grafting procedures to the maxilla for the purpose of a fixed implant-supported prosthetic rehabilitation may spend 12 to 18 months in treatment, with many requiring multiple surgical procedures and numerous clinical visits.

During their years of clinical practice, the authors have experienced a number of patients with severe maxillary atrophy who are not desirous of the aforementioned bone graft solutions. The zygomatic implant protocol described in this report offers a very positive benefit to these patients. Elimination of the need for bone grafting to the maxilla also eliminates

donor and reconstructive site pain, trauma, and swelling. It reduces morbidity and drastically abbreviates the time required for successful treatment. Versus the 12 to 18 months required for grafting protocols, the 12-week zygomatic implant protocol offers the patient a significant decrease in treatment time. Zygomatic implants used in this immediate loading protocol and studied retrospectively had a higher clinical survival rate than implants placed in grafted maxillae.²¹

CONCLUSION

Based on the 96.37% survival rate shown in this study, the use of the zygomatic implant can provide patients with a viable option for restoring the atrophied maxilla. This treatment method should be considered by clinicians and patients interested in avoiding bone grafting procedures in the maxilla.

ACKNOWLEDGMENTS

The authors of this report would like to thank the staff of PI Dental Center for their kind and very gentle treatment of patients; J. Neil Della Croce and Chris Raines for data collection; Fort Washington Dental Laboratory for fabrication of the porcelain-fused-to-gold prostheses; CM Ceramics for construction of the CM Bridges; Dr Chantal Malevez for guidance; and Professor Per-Ingvar Brånemark for inspiration.

REFERENCES

1. Brånemark P-I, Breine U, Adell R, Hansson B, Ohlsson A. Intraosseous anchorage of dental prostheses. Part 1: Experimental studies. *Scand J Plast Reconstr Surg* 1969;3:81–100.
2. Adell R, Lekholm U, Rockler B, Brånemark P-I. A 15-year study of osseointegrated implants in the treatment of the edentulous jaw. *Int J Oral Surg* 1981;10:387–416.
3. Isaksson S, Alberius P. Maxillary alveolar ridge augmentation with onlay bone-grafts and immediate endosseous implants. *J Craniomaxillofac Surg* 1992;20:2–7.
4. Wood R, Moore D. Grafting of the maxillary sinus with intraorally harvested autogenous bone prior to implant placement. *Int J Oral Maxillofac Implants* 1988;3:209–214.
5. Isaksson S, Ekfeldt A, Alberius P, Blomqvist J. Early results from reconstruction of severely atrophic (Class IV) maxillas by immediate endosseous implants in conjunction with bone grafting and Le Fort I osteotomy. *J Oral Maxillofac Surg* 1993;22:144–148.
6. Maló P, Rangert B, Nobre M. All-on-4 immediate function concept with Brånemark System implants for completely edentulous maxillae: A 1-year retrospective clinical study. *Clin Implant Dent Relat Res* 2005;7(suppl 1):588–594.
7. Aparicio C. Tilted implants as an alternative to maxillary sinus grafting: A clinical, radiologic, and Periotest study. *Clin Implant Dent Relat Res* 2001;1:39–49.
8. Krogh P. Anatomic and surgical considerations in the use of osseointegrated implant in the posterior maxilla. *Oral Maxillofac Surg Clin North Am* 1991;3:853–868.
9. Tulasne J. Implant treatment of missing posterior dentition. In: Albrektsson T, Zarb G (eds). *The Brånemark Osseointegrated Implant*. Chicago: Quintessence, 1989:103–116.
10. Balshi S, Wolfinger G, Balshi T. Analysis of 164 titanium-oxide surface implants in completely edentulous arches for fixed prosthesis anchorage in the pterygomaxillary region. *Int J Oral Maxillofac Implants* 2005;20:946–952.
11. Parel S, Brånemark P-I, Ohnrell L, Svensson B. Remote implant anchorage for the rehabilitation of maxillary defects. *J Prosthet Dent* 2001;86:377–381.
12. Bedrossian E, Stumpel L III, Beckley M, Indresano T. The zygomatic implant: Preliminary data on treatment of severely resorbed maxillae. *Int J Oral Maxillofac Implants* 2002;17:861–865.
13. Malevez C, Abarca M, Durdu F, Daelemans P. Clinical outcome of 103 consecutive zygomatic implants: A 6- to 48-months follow-up study. *Clin Oral Implants Res* 2004;15:18–22.
14. Bedrossian E, Rangert B, Stumpel L, Indresano T. Immediate function with the zygomatic implant: A graftless solution for the patient with mild to advanced atrophy of the maxilla. *Int J Oral Maxillofac Implants* 2006;21:937–942.
15. Balshi T, Wolfinger G. Teeth in a Day for the maxilla and mandible: Case report. *Clin Implant Dent Relat Res* 2003;5:11–16.
16. Balshi T, Wolfinger G. Immediate loading of dental implants in the edentulous maxilla: Case study of a unique protocol. *Int J Periodontics Restorative Dent* 2003;23:37–45.
17. Marx RE. Platelet-rich plasma: A source of multiple autologous growth factors for bone grafts. In: Lynch SE, Genco RJ, Marx RE (eds). *Tissue Engineering: Applications in Maxillofacial Surgery and Periodontics*. Chicago: Quintessence, 1999:71–82.
18. Wolfinger G, Balshi T, Rangert B. Immediate functional loading of Brånemark System implants in edentulous mandibles: Clinical report of the results of developmental and simplified protocols. *Int J Oral Maxillofac Implants* 2003;18:250–257.
19. Balshi S, Allen F, Wolfinger G, Balshi T. A resonance frequency analysis assessment of maxillary and mandibular immediately loaded implants. *Int J Oral Maxillofac Implants* 2005;20:584–594.
20. Senders C, Emery B, Sykes J, Brodie H. A prospective, double-blinded, randomized study of the effects of perioperative steroids on palatoplasty patients. *Arch Otolaryngol Head Neck Surg* 1996;122:267–270.
21. Keller E, Tolman D, Eckert S. Surgical-prosthetic reconstruction of advanced maxillary bone compromise with autogenous onlay block bone grafts and osseointegrated implants: A 12-year study of 32 consecutive patients. *Int J Oral Maxillofac Implants* 1999;14:197–209.